Quaternary Science Advances 12 (2023) 100120

Contents lists available at ScienceDirect

Quaternary Science Advances

journal homepage: www.sciencedirect.com/journal/quaternary-science-advances

Early Bronze Age violence in Ojo Guareña (Merindad de Sotoscueva, Burgos, Spain). Perimortem modifications in two male individuals

Borja González-Rabanal [a,*], Ana B. Marín-Arroyo [a], Marco Vidal-Cordasco [a], Miguel Ángel Martín [b], Ana Isabel Ortega [c,d]

[a] Grupo de I+D+i EvoAdapta (Evolución Humana y Adaptaciones durante la Prehistoria), Dpto. Ciencias Históricas, Universidad de Cantabria, Av. Los Castros 44, 39005, Santander, Spain
[b] Sociedad Española de Espeleología y Ciencias del Karst, Spain
[c] CENIEH –Centro Nacional sobre la Evolución Humana, Paseo Sierra de Atapuerca 3, 09002, Burgos, Spain
[d] Fundación Atapuerca, Carretera Logroño km 44, 09198, Ibeas de Juarros, Burgos, Spain

ARTICLE INFO

Keywords:
Northern iberia
Recent prehistory
Human remains
Taphonomy
Lethal injuries

ABSTRACT

This paper analyses the taphonomic modifications of the human remains identified within Cueva Palomera, the main entrance to Ojo Guareña karstic system (Merindad de Sotoscueva, Burgos, Spain). The human skeletons were found deposited over the cave floor of two high, narrow and hard-to-reach sectors called *Terraza del Enterramiento de la Galería Principal* and *Galería Sepulcral de la Sima Dolencias*. Both sites represent primary depositions, in anatomical association and preserved partial joints but without grave goods. These humans are directly dated between 2000–1750 cal BC, suggesting that both events took place within a short time frame during the Early Bronze Age. The anthropological and taphonomic studies show that two adult male individuals suffered different types of lesions in their cranium, clavicle, and ribs, including traumatisms and cut marks. Taphonomic techniques have identified diagenetic and biostratinomic modifications, helping the assessment of their postmortem and perimortem interval. The morphological features of these modifications confirm that both individuals suffered lesions performed during the perimortem interval, suggesting their likely cause of death. The concentration of the injuries and the contemporaneity of both individuals are coherent with intentional anthropic action, indicating that they could result from a violent conflict.

1. Introduction

Violence is one of the oldest human behaviours documented in Prehistory. The first evidence of interpersonal violence comes from the Middle Pleistocene site of the Sima de los Huesos (Sierra de Atapuerca, Burgos) (Sala et al., 2015, 2016). Lethal and nonlethal trauma cases have also been identified among Neanderthals (Trinkaus and Zimmerman, 1982; Berger and Trinkaus, 1995; Zollikofer et al., 2002; Gardner and Smith, 2006) and other archaic hominins (Montgomery et al., 1994; Balzeau et al., 2003; Wu et al., 2011). However, scarce evidence from the Upper Palaeolithic sites is known (Henry-Gambier et al., 2001; Trinkaus and Svoboda, 2006; Trinkaus and Buzhilova, 2012; Kranioti et al., 2019). The number of traumatic lesions increased over time and became more frequent during the Mesolithic in Europe (Roksandic, 2006; Roksandic et al., 2006; Schulting, 2009; Estabrook, 2016) and in the context of the seminomadic African hunter-gatherers (Mirazón Lahr et al., 2016; Crevecoeur et al., 2021). With the arrival of the Neolithic, an intensification of violence compared to previous periods is observed. This trend can be detected in the well-known mass graves associated with the LBK culture in Central Europe (Meyer et al., 2009, 2014, 2015, 2018; Teschler-Nicola, 2012; Wahl and Trautmann, 2012; Fibiger et al., 2023) and in other European regions (Schulting and Fibiger, 2012; Silva et al., 2012; Sánchez-Barba Muñoz et al., 2019; Alt et al., 2020). Violence is also widely documented in Bronze Age Europe (Jiménez-Brobeil et al., 2009; Pasini et al., 2019; Molloy and Horn, 2020), although the osteological evidence of violence is limited in the Iberian Bronze Age, something that clashes with archaeological evidence such as defensive structures or the improvement of weapons (e.g., Argar) (Fernández Manzano, 1985).

Interpersonal violence is not unknown among the first farming societies of Iberia (Alonso Bercianos and Díaz Navarro, 2021). In recent years, osteoarchaeological research has been carried out to investigate

* Corresponding author.
E-mail address: borjagrabanal@gmail.com (B. González-Rabanal).

https://doi.org/10.1016/j.qsa.2023.100120
Received 29 April 2023; Received in revised form 16 August 2023; Accepted 28 August 2023
Available online 29 August 2023

violence in Prehistory, highlighting the works of A.M. Silva on the Portuguese region (Silva and Marques, 2010; Silva et al., 2012); S. Jiménez-Brobeil in southern Iberia (Jiménez-Brobeil et al., 2009, 2014); D. Campillo in the Mediterranean area (Campillo and Baxarias, 2008) together with other colleagues (Soriano et al., 2015; Moreno-Ibáñez et al., 2021); and different researchers for central plateau (Esparza Arroyo et al., 2008; Nájera et al., 2010; Fabián García and Blanco González, 2012; Díaz-Navarro, 2020). Similarly, the archaeological record of northern Iberia has also provided unanswerable evidence of different types of violence through the study of skeletal remains, remarking the research conducted by F. Etxeberria on prehistoric samples from Basque Country (Etxeberria and Vegas, 1988, 1992; Armendariz et al., 1994; Etxeberria et al., 2005; Vegas et al., 2012), and more recently by T. Fernández Crespo in the same area (Fernández-Crespo, 2016, 2017; Fernández-Crespo et al., 2018, 2020). The archaeological sites with clear evidence of violence during the Recent Prehistory in northern Iberia are mapped in Fig. 1. For the Late Neolithic/Chalcolithic transition are listed: Las Cáscaras (Etxeberria and Vegas, 1992) in Cantabria; San Juan Ante Portam Latinam, Las Yurdinas II and Alto de la Huesera (Etxebarría et al., 1996; Vegas et al., 2012; Fernández-Crespo, 2017; Fernández-Crespo et al., 2018) in Alava; and Longar and La Peña de Marañón (Soto and Martija, 1995; Fernández-Crespo, 2016) in Navarra. For the Chalcolithic: Pico Ramos (Baraybar and La Rua, 1995) in Vizcaya; Los Llanos and La Mina in Álava (Etxebarría et al., 1996); La Atalayuela (Andrés and Barandiarán, 2004) in La Rioja; Aizibita and Peña del Castillo II (Beguiristain and Etxeberría, 1994; Etxebarría et al., 1996) in Navarra; and El Mirador and El Hundido (Alonso, 2015; Iglesias-Bexiga et al., 2022) in Burgos. For the Bronze Age: Las Pajucas (Etxebarría et al., 1996) in Vizcaya, Los Rompizales and Las Arnillas (García-Ruíz, 1992; Velasco-Vázquez and Esparza-Arroyo, 2016) in Burgos; and La Saga (Díaz-Navarro, 2020) in Navarra. And finally, the exceptional cases of La Hoya (Fernández-Crespo et al., 2020) in Álava and Las Rabas (Bolado del Castillo et al., 2019) in Cantabria, both dated to the Iron Age.

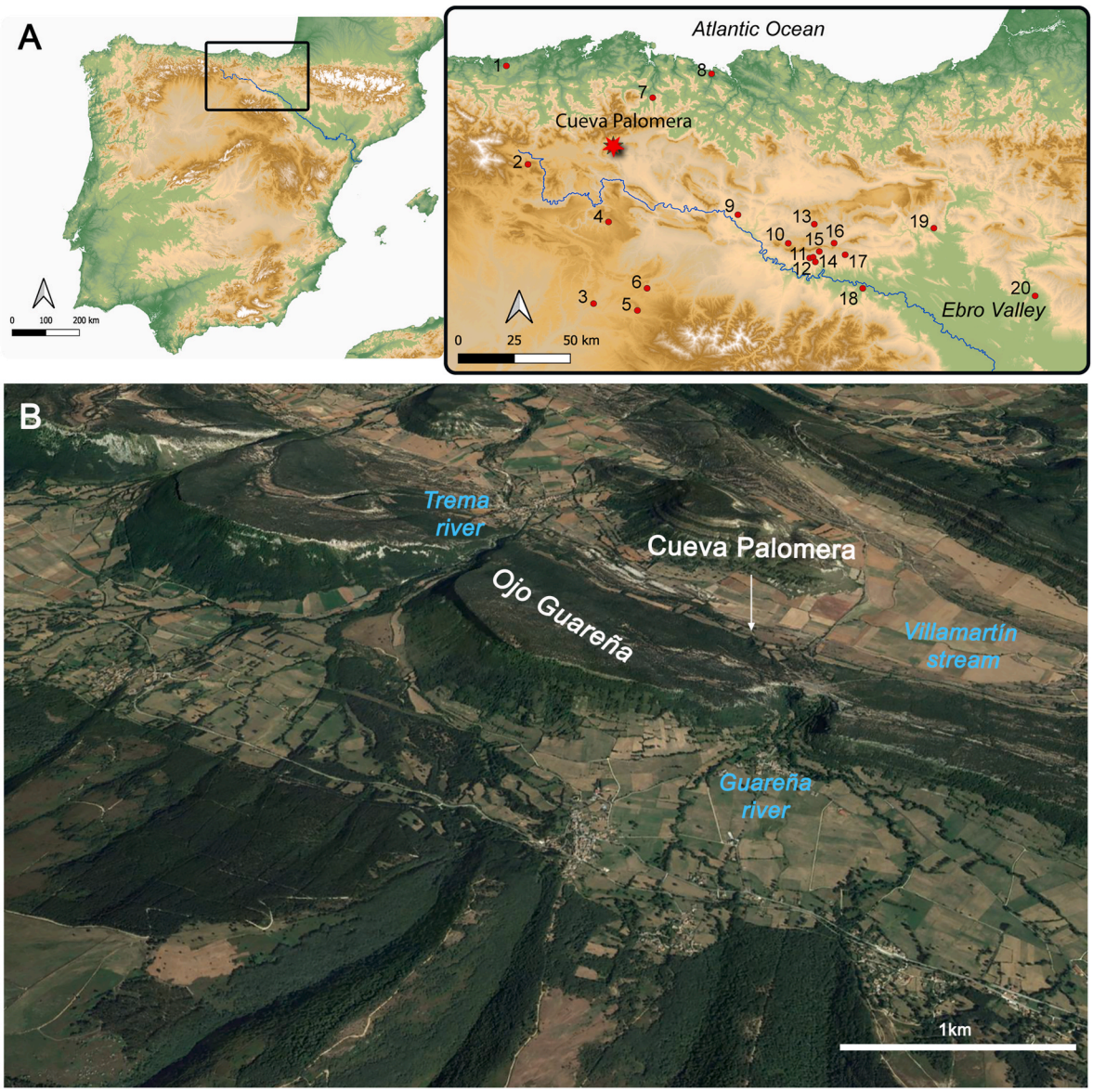

Fig. 1. A) Map showing the location of the study area in northern Iberia. The red star shows the location of Cueva Palomera. Red dots indicate the archaeological sites cited in the text: 1. Las Cáscaras; 2. Las Rabas; 3. Los Rompizales; 4. Las Arnillas; 5. El Mirador; 6. El Hundido; 7. Las Pajucas; 8. Pico Ramos; 9. La Mina; 10. Las Yurdinas II; 11. La Hoya; 12. Alto de la Huesera; 13. Peña del Castillo II; 14. San Juan Ante Portam Latinam; 15. Los Llanos; 16. La Peña de Marañón; 17. Longar; 18. La Atalayuela; 19. Aizibita; 20. La Saga. B) Aerial photography indicates the cave's location and the area's main geographical elements. (For interpretation of the references to colour in this figure legend, the reader is referred to the Web version of this article.)

The archaeology of conflict can be explored in depth from the analysis of indirect archaeological evidence -defensive structures, battlefields (Jantzen et al., 2011), rock art, and weapons (Christensen, 2004; Guilaine and Zammit, 2004; López-Montalvo, 2015)-, but osteoarchaeology is the only direct indicator of violent episodes at specific people in Prehistory and, therefore, can give us solid information about their implications and the reality of a violent event (Martin and Harrod, 2015). However, how the evidence of conflict is difficult to demonstrate through the analysis of human remains due to the majority absence of soft tissues because of preservation biases (Knüsel and Robb, 2016), bioarchaeological studies rise as a tool to reconstruct the history of violence among prehistoric societies (Walker, 2001). For the osteoarchaeological study of violent injuries, forensic analyses of burial contexts are essential to facilitate the interpretation of the casuistry, the correct identification of ante, peri or postmortem injuries, the type of weapons used and the type of violence inflicted (Lovell, 1997; Sauer, 1998; Walker, 2001; Katzenberg and Saunders, 2008; Kimmerle and Baraybar, 2008). In the same way, the application of taphonomic criteria is relevant since it may provide information about the site formation and postdepositional processes (Lyman, 1994a; Fernández-Jalvo and Andrews, 2016; Stodder, 2018), but also for assessing the timing of the taphonomic modifications of the human bone assemblages (biostratinomic vs diagenetic processes) (Sorg and Haglund, 1996; Pokines and Symes, 2014; Schotsmans et al., 2017). The combination of both disciplines has allowed the identification of an increasing number of antemortem and perimortem traumas in the human skeletal assemblages of sedentary farming communities (Larsen, 2015), suggesting that there must have been much more violence cases than previously thought. Furthermore, the increase of testimonies among the last hunter-gatherer groups and sedentary societies has led to an archaeological debate about the origin of warfare (Keeley, 1996; Guilaine and Zammit, 2004; Thorpe, 2005) and how our ancestors engage in forms of organized violence (Ehrenreich, 1997; Otterbein, 1997; Christensen, 2004; Kissel and Kim, 2019). A much more difficult task is to detect the causes of these conflicts. Researchers have suggested different explanations for the warfare, such as the depletion of available sources, ecological imbalance, population density or migrations, although these factors may have been considered depending on each context.

With the aim to identify new violent behaviours in northern Iberia during Recent Prehistory, this paper focuses on the osteoarchaeological analysis of two human skeletons deposited in Cueva Palomera (Ojo Guareña, Burgos) using a taphonomic and forensic approach, that can be implemented as a methodological framework in the future, especially for analysing old collections of human remains currently curated in museums.

2. Materials

2.1. Ojo Guareña karstic system

The Ojo Guareña karstic system is located in the north of the Iberian Peninsula in the municipality of the Merindad de Sotoscueva (Burgos) (Fig. 1A). It is placed on the southern slope of the Cantabrian Mountain range and the upper Ebro River basin, two well-differentiated biogeographical regions: Eurosiberian and Mediterranean (Ortega et al., 2013). This karst consists of 14 connected caves and a network of galleries and passages that reaches 110 km, constituting one of the most extended underground systems in Europe and is listed as the Natural and Cultural Heritage of Spain. These caves are distributed over six overlapping sub-horizontal levels of cretaceous limestones formed by the Guareña and Trema rivers and the Villamartín stream (Fig. 1B). This complex was explored by the *Grupo Espeleológico Edelweiss* (GEE) since the 1960s, who discovered different archaeological sites during speleological explorations (Ortega and Martín, 1986). As a result of their systematic surveys, this karst complex contains an impressive cultural sequence of human activities from at least the Middle Palaeolithic to the Middle Ages (Ortega and Martín, 2001) (Fig. 2A). The archaeological evidence includes living areas (Ortega et al., 2013; Navazo et al., 2021), rock art (Uribarri and Liz, 1973; Gómez-Barrera et al., 2003; Ortega and Martín, 2015; Ortega et al., 2020), footprints (Ortega et al., 2021a), isolated artefacts and burials (Ortega et al., 2013). In particular, this research focuses on the Cueva Palomera, the main entrance to Ojo Guareña (Fig. 1B).

2.2. Cueva Palomera

The entrance to Cueva Palomera is located at the bottom of an old sinkhole of the Villamartín stream (Ortega and Martín, 2023), providing access via the slope of *Rampa de Palomera* to the cave's fourth level of karst and its main gallery, which extends for almost 1 km (Fig. 2B). The prehistoric human activities within the cave are varied but little studied. In 1972, M. Soledad Corchón carried out a test pit in the vestibule, documenting almost 5 m deep archaeological levels with prehistoric ceramics. However, the results of this excavation were not published in detail, and the materials are currently stored at the Archaeological Museum of Burgos (Ortega and Martín, 1986). Besides, in *Rampa de Palomera* there is a natural ditch caused by the action of the infiltration waters that shows a powerful cultural sequence with several fumière-type stratigraphic units dated from the Neolithic to the Bronze Age. These findings suggest the existence of an important archaeological site from Recent Prehistory in the cave entrance (Ortega et al., 2021b). Further inside, there are seven areas with rock art performed by hunter-gatherers and farming communities from the Azilian to the Bronze Age. In this research, we study two single funerary sites discovered by GEE in 1981 and 2002 in different narrow and hard-to-reach areas of the main gallery and recovered by A. I. Ortega during the 2016 and 2018 surveys (Figs. 2C and 3A).

2.2.1. Terraza del Enterramiento de la Galería Principal (TE)

TE is located on a ledge 7 m high by 1 m wide above the *Galería Principal.* This site is located 500 m far from the Palomera entrance (Figs. 2C and 3B). The human skeleton was discovered over the floor surface of the ledge, which was expressly prepared for its deposition, in anatomical association but without any preserved anatomical joints and without any type of grave goods (Fig. 3C). During the postmortem interval, the place was probably disturbed because of faunal activity, which could have modified the primary position of the burial, disarticulating the bones.

2.2.2. Galería Sepulcral de la Sima Dolencias (GS)

GS is placed in the upper level of *Sima Dolencias,* a large room on whose vault the waterfall of the Villamartín stream precipitates after saving a drop of 54 m high (Fig. 3B). The individual was in the floor surface, partially covered by a thin layer of silts, in the lateral corridor of the small northern passage. This little corridor is located 30 m above the main gallery and 1000 m far from the Palomera entrance (Figs. 2C and 3A). The skeleton appeared in partial anatomical connection and was flexed on his right side, although he did not have grave goods either (Fig. 3C). This deposit was affected, at a later time, by the digging of a trench, resulting in the loss of the skull and some long bones and the disarticulation of some joints.

3. Methods

3.1. Radiocarbon dating

Bone fragments were taken from the two individuals to date in both burial contexts. Sampling was based on selecting long human bones with a dense cortical to ensure a high-quality standard of collagen preservation. The human bone samples were sent to the BETA Analytic laboratory (Miami, Florida). The dates were calibrated in OxCal v4.4.4 (Bronk Ramsey, 1995) using the IntCal20 calibration curve (Reimer

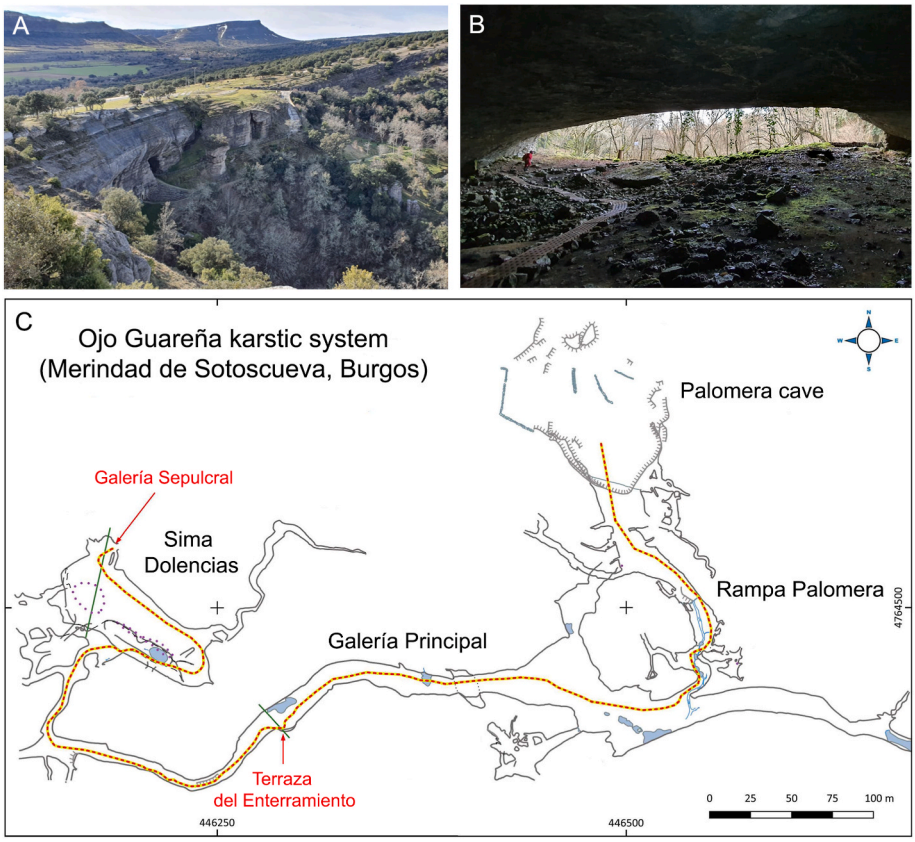

Fig. 2. A) View of the Ojo Guareña Natural Monument from outside. B) Main entrance to Cueva Palomera. C) Plan of the karstic system with the places referred to in the text. The line of red and yellow dots indicates the route from the entrance. The red arrows show the location of the burial sites (Map: Grupo Espeleológico Edelweiss, 1986; modified by A. I. Ortega and A. San Martín). (For interpretation of the references to colour in this figure legend, the reader is referred to the Web version of this article.)

et al., 2020). The results are presented at a 95.4% probability.

3.2. Anthropological analysis

Taxonomical and anatomical identification was undertaken with an anthropological atlas (White and Folkens, 2005) and the reference collection of EvoAdapta Group (University of Cantabria). Teeth were classified according to the FDI notation. The sex of the individuals was estimated based on the cranium, mandible and/or coxal morphological landmarks (Buikstra and Ubelaker, 1994). The age of the individuals was determined using cranial suture closure (Meindl and Lovejoy, 1985), the human tooth development and eruption (AlQahtani et al., 2010), dental wear (Smith, 1984), the metamorphosis of the auricular surface of the ilium (Lovejoy et al., 1985), the fusion of the sternal end of the clavicle (Szilvássy, 1977) and bone fusion (Scheuer and Black, 2000). Pathologies were identified using recognised palaeopathological guidelines (Mann and Hunt, 2005; Aufderheide and Rodriguez-Martin, 2011). Dental calculus was estimated according to the categories proposed by Buikstra and Ubelaker (1994). Stature was calculated through the máximum length of long bones using the formulas proposed by Trotter and Gleser (1952) and corrected by Mays (2016) with linear regression formulas.

3.3. Taphonomic analysis

To assess the skeletal representation, several quantification units were applied (Lyman, 1994b): Number of Remains (NR), Minimum Number of Elements (MNE) and Minimum Number of Individuals (MNI). To determine the degree of fragmentation and the preservation of the assemblage two indexes were calculated: Fragmentation Ratio (FR) (Richardson, 1980) and Bone Representation Index (BRI) (Bello and Andrews, 2006). The taphonomic analysis was carried out by identifying the different biostratinomic and diagenetic modifications on the skeletal remains using macroscopic observations (Fernández-Jalvo and Andrews, 2016). Every anatomical element was observed under a LEICA S8 APO stereoscope with 10x eyepieces in search of bone surface alterations. To ascertain the timing of bone fracture (perimortem vs postmortem), the following taphonomic approaches were carried out in different skeletal remains. Firstly, cranial breakage patterns were studied using the fracture parameters proposed by Sala et al. (2016). *1) outline*: linear, depressed or stellate (Galloway and Wedel, 2014); *2) location*: above, below or in the "hat brim line"; *3) trajectory*: not cross suture or crossing suture (Kremer et al., 2008); *4) angle*: right or oblique; *5) cortical delamination*: presence or absence; and 6) *edge texture*: smooth or jagged (Jordana et al., 2013). Secondly, for analysing the long bones breakage patterns, the following fracture properties were considered according to Villa and Mahieu (1991). *1) outline*: longitudinal, transverse and curved; *2) angle*: right, oblique or mixed; *3) edge:* smooth or jagged,*4) shaft circumference*: 1, 3/4, 1/2 or 1/4; and *5) shaft fragment*: <1/4, 1/4, 2/4, 3/4 and 1 of the total length of the bone. Alike, the assessment of the rib fracturation was conducted by considering the presence/absence of the macroscopic traits defined by Scheirs et al. (2018). *1)* incomplete fractures, *2)* plastic deformation, *3)* peel, *4)* fold, *5)* longitudinal lines, and *6)* internal/external different appearance. Finally, cut marks were examined following the categories established by Binford (1981): *1)* skinning, *2)* dismembering, and *3)* defleshing.

4. Results

4.1. TE individual

4.1.1. Radiocarbon results

The human bone sample from TE was dated to 3530 ± 30 (Beta-473659) with a calibration interval of 1945-1751 cal BC. This date places this burial site in the II millennium cal BC, belonging to the regional Early Bronze Age.



Fig. 3. Left: TE individual; Right: GS individual. A) Profile of the Galería Principal and Sima Dolencias at the level of the archaeological sites (Map: A. I. Ortega, A. San Miguel, F. Ruiz). Red dots show the position of the skeletons over the main gallery. B) Location of the burial sites within the cave (photograph of the Sima Dolencias: Pedro Carazo). Red dots indicate the place where the human individuals were discovered. C) Detail of the human skeletons before excavation. Scales: 10 cm. (For interpretation of the references to colour in this figure legend, the reader is referred to the Web version of this article.)

4.1.2. Anthropological results

This individual is represented by an almost complete skeleton in a good state of preservation and in anatomical association (Fig. 3C). Despite its good preservation, some teeth, vertebrae, carpals, tarsals, and phalanges were lost. In contrast, others, such as the scapulae, coxal bones, some long bones, and especially the cranium, were highly fractured and completely disarticulated (Table 1, Fig. 4A).

The sexual determination of the individual has been made based on the morphological traits of the cranium, mandible and pelvis. The nuchal crest, the supraorbital torus, the glabella and the mastoid process of the cranium are not very robust, but they are considerably marked. The mandible shows the eversion of the gonian angle, as well as the acute angle of the sigmoid notch, indicating that it belongs to a male individual. Regarding the coxal bones, the angle of the sciatic notch and the preauricular sulcus corroborate the male sex of the individual. Furthermore, the long bones of this individual are very robust. All the teeth had fully erupted, including the M_3 (18 and 28), indicating an age above 22 years. Based on bone fusion, all epiphyses had just fused, confirming that this individual was at least 25 years of age. The degree of closure of the coronal, sagittal and lambdoid sutures indicates an age between 30 and 40 years. In turn, the palatal suture suggests that the age of death was between 18 and 50 years. The sternal end of both clavicles had been completely fused, indicating a minimum age of 30 years. Finally, the morphology and texture of the auricular surface of the ilium are compatible with a phase 3–5 of development, which suggests an age between 30 and 44 years. This evidence confirms that it is a mature adult individual. The stature estimation was conducted through the maximum length of the femur, providing a stature of 1.70 m.

Twenty-four teeth have been preserved: 14 upper (11, 12, 13, 16, 17, 18, 21, 22, 23, 24, 25, 26, 27 and 28) and 10 lower (32, 33, 35, 41, 42, 43, 44, 45, 46 and 47). The remaining teeth have not been recovered, but their alveoli are exposed, so they were lost after the individual's death. The only exceptions are the dental pieces 14 and 48, whose alveoli had been resorbed and thus were lost in an antemortem interval. All the teeth show high occlusal wear (degree 3–5) and dental calculus on their lingual and buccal surfaces (degree 1, small amount). Ten teeth (11, 13, 21, 22, 24, 27, 33, 34, 35 and 44) have a small line of hypoplasia. In addition, tooth 17 presents distal caries in the neck of the tooth. The mandible presents mandibular torus and the maxilla lingual exostosis. Finally, all the dental pieces show periodontitis of a medium degree. Regarding postcranial pathologies, spondyloarthritis has been detected in four vertebrae. This individual shows a higher degree of robustness in the hindlimbs than in the forelimbs, as well as marked muscle insertions. Likewise, osteophytes have been observed in the leg bones, while not in the arm bones. It is worth noting the osteophytes identified in the patella, the calcaneus or the phalanges of the foot. The iliac crest of the right coxal bone also presents osteophytes. Finally, vascular grooves have been detected both in the tibiae and also in the femurs.

4.1.3. Taphonomic results

The skeletal profile representation of the human remains from TE is presented in Table 1. The human bone assemblage is composed of 395 NR belonging to 170 MNE and an MNI of 1. The skeletal representation and the anatomical association of the skeleton suggest that the individual was primarily deposited in the ledge and later disarticulated. This

Table 1
Human skeletal profile representation from TE and GS individuals.

Element	TE individual					GS individual				
	NR	MNE	MNI	FR	BRI	NR	MNE	MNI	FR	BRI
Cranium	72	1	1	72	100%	0	0	0	0	0%
Maxillae	3	1	1	3	100%	0	0	0	0	0%
Mandible	1	1	1	1	100%	1	1	1	1	100%
Teeth	24	24	1	1	75%	5	5	1	1	16%
Hyoides	2	1	1	2	100%	6	1	1	6	100%
Cervical vt	6	4	1	1.5	57%	7	7	1	1	100%
Thoracic vt	14	10	1	1.4	83%	12	10	1	1.2	83%
Lumbar vt	14	5	1	2.8	100%	14	5	1	2.8	100%
Indet vt	4	1	1	4	0%	2	0	0	0	0%
Sacrum-coccyx	15	1	1	15	100%	3	1	1	3	100%
Os coxae	14	1	1	14	100%	10	1	1	10	100%
Ribs	68	24	1	2.8	100%	51	24	1	2.1	100%
Scapula	10	2	1	5	100%	1	1	1	1	50%
Clavicle	2	2	1	1	100%	2	2	1	1	100%
Sternum	2	1	1	2	100%	7	1	1	7	100%
Humerus	3	2	1	1.5	100%	6	2	1	3	100%
Ulna	2	2	1	1	100%	2	2	1	1	100%
Radius	3	2	1	1.5	100%	1	1	1	1	50%
Carpals	15	15	1	1	94%	5	5	1	1	31%
Metacarpals	10	10	1	1	100%	4	4	1	1	40%
Hand phalanges	23	23	1	1	82%	5	5	1	1	18%
Femur	23	2	1	11.5	100%	0	0	0	0	0%
Patella	2	2	1	1	100%	0	0	0	0	0%
Tibia	8	2	1	4	100%	0	0	0	0	0%
Fibula	7	2	1	3.5	100%	0	0	0	0	0%
Tarsals	8	8	1	1	80%	1	1	1	1	10%
Calcaneus	2	2	1	1	100%	0	0	0	0	0%
Talus	2	2	1	1	100%	0	0	0	0	0%
Metatarsal	10	10	1	1	100%	0	0	0	0	0%
Foot phalanges	7	7	1	1	25%	1	1	1	1	4%
Indet	19	0	0	0	0%	9	0	0	0	0%
Total	**395**	**170**	**1**	**2.3**	**80%**	**155**	**80**	**1**	**1.9**	**38%**

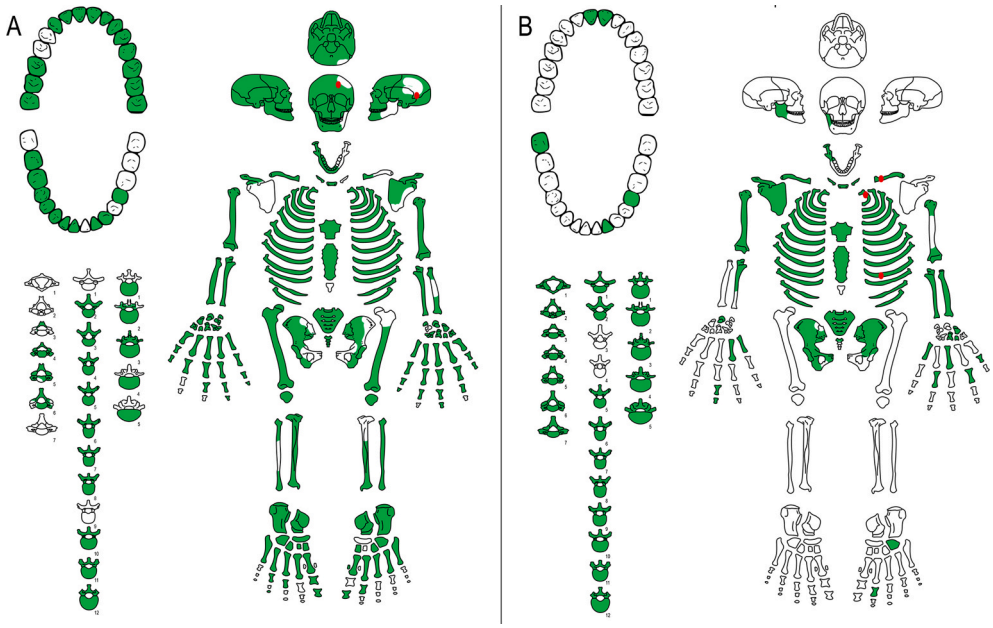

Fig. 4. Skeletal representation of the individuals. Location of the perimortem injuries in red dots. Preserved anatomical elements are in green. A: TE individual; B: GS individual. (For interpretation of the references to colour in this figure legend, the reader is referred to the Web version of this article.)

assemblage had an FR of 2.3. However, if this index is analysed by anatomical elements, significant fluctuations can be observed. The highest FR values were obtained in the cranium (FR = 72), the sacrum (FR = 15), the coxal bones (FR = 14) and the femur (FR = 11.7), indicating the high fracturation suffered by these bones. Other elements, such as the maxilla, scapulae, tibiae and fibula, had an FR ranging from 3 to 5. Other bones provided rates below 2, such as vertebrae or ribs. The rest of the skeletal elements had no fractures. The BRI obtained for the TE individual was 80%, showing the excellent preservation of the skeleton. Most anatomical elements are represented with 100% of the expected bones. Other remains have been preserved between 70 and 100%, such as teeth, thoracic vertebrae, carpals, hand phalanges and

tarsals. The only bones that had lower percentages were the cervical vertebrae (BRI = 57%) and the foot phalanges (BRI = 25%).

The study of cranial fractures of the TE individual shows a high fracturation of the cranium, especially in the left vault. Most of the cranium fractures display linear-curved fracture outline (94%). Still, two traumatisms have been identified in the frontal (trauma 1) and left parietal bone (trauma 2) (Fig. 5). Both are stellate/depressed fractures consisting of multiple radiating linear fractures originating at each point of impact and extending almost the entire cranium, mainly along the frontal (crossing the frontal squama and glabella regions) from trauma 1, and along the left parietal and right parietal (crossing the parietal tuber) and left temporal bones from trauma 2. No evidence of healing is documented in both traumas. The fracture location has been analysed according to the "Hat Brim Line" rule, showing that 50% of the fractures are above, 34% within, and 16% below the "Hat Brim Line". Regarding the fracture trajectory, 19% of the fractures cross cranial sutures, while the remaining fractures do not cross sutures. Concerning the fracture angle, 97% of the total sample displayed oblique angles, while 3% of them were defined as right angles. Similarly, the fracture edge texture was identified as smooth in 96% of the cases. Only 3% of the fractures show jagged edge texture. And respecting cortical delamination, it was present in 56% of the cranium fragments. The long bone breakage patterns in the TE individual reveal that 65% of the long bones display fractures. As for the fracture outline, all the broken long bones show transversal fractures. The fracture angle shows more significant heterogeneity, being 30% mixed, 63% oblique and 7% right. Instead, the

Fig. 5. Perimortem fractures of the TE skull. White arrows show cortical delamination, oblique angles, and smooth edges. Scale: 1 cm. Numbers 1 and 2 indicate the impact point.

fracture edge is jagged in 100% of the fractures. Shaft circumference is complete in 43% of the sample, while it is 1/2 of the total circumference in 57% of the cases. And, regarding the shaft fragment, the larger fragments dominate with 33% of the long bones being complete, 13% of 3/4 and 39% of 2/4. The smaller fragments show a 4% of 1/4 and 11% of <1/4 of the total length. The analysis of rib fracturation indicates that 84% of the ribs are fractured. They all display transverse fractures with mixed/right angles and jagged edges. Two incomplete fractures have been identified concerning the macroscopic traits studied in this work, while four ribs showed longitudinal lines. No evidence of plastic deformation, peels, folds and internal/external differences in appearance have been recorded in the rib assemblage. No cut marks have been documented on the skeletal remains of this individual.

Finally, diagenetic processes have also been documented in the TE individual. Weathering has affected 43% of the NR, although the most significant weathering degrees were stages 1 and 2. Calcite concretions are present in 64% of the NR, but they are weak and superficial. In the same way, water dissolution has modified the 66% of the skeleton, with low and medium degrees. Other diagenetic agents, such as manganese staining and bacterial activity, have altered the bones by 19% and 15% of the NR, respectively. Other postmortem taphonomic processes have been identified, such as small black thermoalterations in 4% of the NR, and trampling in 5% of the NR.

4.2. GS individual

4.2.1. Radiocarbon results

The human sample taken from the GS individual was dated to 3550 ± 30 BP (Beta-554338), with a calibration interval of 2014-1771 cal BC, consistent with the Early Bronze Age and similar to the radiocarbon date obtained in the TE individual.

4.2.2. Anthropological results

To this individual, a half skeleton in a good state of preservation and partial anatomical connection is attributed, yet, an essential number of anatomical elements were lost or slightly disarticulated. Most of the vertebrae, some ribs and sacrum still preserved articulated joints, while the postcranial skeleton was found in anatomical association but disarticulated (Fig. 3C). Only half of the bones have been preserved, such as a mandibular fragment and five teeth, the axial skeleton with most of the vertebrae, the ribs, both clavicles and a scapula, the arm bones excepting the right radius, a few carpals and phalanges, as well as the pelvis almost complete, with both coxal bones and the sacrum. The skull and all the hindlimb bones are not represented (Table 1 and Fig. 4B).

The sexual determination of the individual has been made exclusively from the morphological landmarks of the pelvis and mandible. The angle of the sciatic notch is very acute. The sacrum, which is completely preserved, is not deeply excavated. Both traits are habitually identified in male individuals. The sigmoid notch and the eversion and roughness of the gonian angle confirm that it is a male individual. In addition, the robustness of the long bones is in line with this determination. All the teeth had fully erupted, as indicated by the presence of the dental piece 48, which is characteristic of adult individuals of at least 22 years of age. Bone fusion had been completed in all skeletal bones indicating that this individual was at least 25 years of age. The sternal end of both clavicles is already fused, indicating a minimum age of 30 years. The morphological characteristics of the articular face of the ilium with the sacrum are compatible with phases 3–5 of development, which suggests an age between 30 and 44 years. All these morphological traits confirm that it is a mature adult individual. In the absence of other complete long bones, the height of this individual has been estimated from the maximum length of the right humerus, and the left ulna and radius. The size of this individual has been calculated between 1.62 m and 1.70 m.

The paleopathological study has not identified lesions in the few preserved teeth. These consist of teeth 11 and 31, dental piece 48, and teeth 32 and 34. The teeth have low occlusal wear (degree 3), but all of them show dental calculus on their lingual and buccal surfaces (degree 1, small amount). Regarding the postcranial skeleton, osteophytes have been identified at the insertion of the flavum nerve, as well as several Schmörl's nodules (herniations of the nucleus pulposus) and osteolytic lesions in the vertebrae, as well as osteophytes at the sternal ends of the ribs. On the other hand, the beginning of scoliosis has been documented in three thoracic vertebrae. Finally, the left ulna has an antemortem fracture at the level of the distal metaphysis. The few remains of long bones have limited the analysis of activity markers, highlighting the finding of an enthesopathy in the proximal epiphyses of both ulnae, and very high degrees of robustness in both humeri, right scapula, and clavicles.

4.2.3. Taphonomic results

The quantification of the human skeletal remains at GS provided an NR of 155, belonging to 80 MNE and an MNI of 1 (Table 1). This assemblage had an FR of 1.9. In this case, the variations between anatomical elements were minor. The element that yielded the highest FR was the coxae, with a value of 10, and the sternum, with a value of 7. It should be noted that the hyoid bone was preserved, but it presented a high fracture (FR = 6). The only additional elements found to be fractured were the vertebrae, ribs, sacrum, and humerus, whose FR fluctuated between 1 and 3. The BRI of the GS individual is 38% showing a differentiated distribution. Although many recovered bones are represented with BRI of 100%, such as vertebrae, ribs, and arm bones, others have very low percentages. Among the latter, it is worth highlighting the teeth, carpals, metacarpals, hand phalanges, tarsals and foot phalanges with very low BRI percentages ranging between 4 and 40%. The skull and most of the hindlimb bones have not been documented. Despite being deposited in anatomical connection, this distribution indicates the loss of critical skeletal portions, corroborating the burial alteration due to the trench.

Cranial breakage patterns have not been able to be analysed due to the absence of cranium elements in this individual. However, the study of the long bone breakage patterns in the GS individual indicates that 78% are fractured. The fracture outline shows that all the fractures are transverse. Regarding the fracture angle, 71% of the fractures are mixed, while 29% are oblique. As in the TE individual, the fracture edge is jagged in 100% of the fractures. The shaft circumference is complete in all the samples. And, regarding the shaft fragment, category 1 dominates, with 45% of the long bones being complete, 11% of 2/4 and 44% of 1/4. The left thoracic region of the GS contains fractures and cut marks (Fig. 6). Concerning the rib breakage patterns, 46% of the ribs are fractured. They are transverse fractures with mixed/right angles and jagged edges. These fractures are located along two main axes, in the posterior and lateral arches of the ribs, with an outside-in posterolateral direction. Four ribs present incomplete fractures, ten show longitudinal cracks, two display plastic deformation, and four show differences in appearance between the internal/external edges (Fig. 6C). No signs of peels or folds have been identified. Instead, the right ribs do not present any type of taphonomic alteration, and most of them remain complete. In addition, 20 cut marks were identified along this anatomical region. Nine are visible in the posterior view of the left clavicle near the sternal extremity (Fig. 6A). They are thin, oblique and show overlappings between them. However, their general direction indicates a slightly oblique anteroposterior entrance. Nine cut marks are also located in the upper part of the first left rib close to the vertebral end (Fig. 6B). They are deep, short and clustered cut marks with an anteroposterior trajectory and parallel. And, two more are in the ninth left rib near the lower border of the sternal end and slightly separated from each other (Fig. 6D). They have somewhat different characteristics from the previous ones, being shorter, with a posterolateral direction and with a broader notch at the end of each cut mark. No additional cut marks have been noted on the rest of the skeleton.

Other diagenetic modifications have also modified the GS skeleton.



Fig. 6. Anthropic modifications from the GS individual. A) Cut marks in the left clavicle. B) Cut marks in the first left rib. C) Fracturation of the left thoracic region. D). Cut marks in the ninth left rib.

26% of the NR showed weathering marks (stage 1). Calcite concretions were identified in 43% of the remains, and the lower stages of water dissolution were present in 44% of the NR. On the other hand, manganese staining and bacterial activity are less represented, with 1% and 6% of the NR. The skeletal remains of the GS individual have also been affected by small black thermoalterations and trampling in 7% and 1% of the NR, respectively.

5. Discussion

5.1. A snapshot of violence during the Early Bronze Age

Radiocarbon dating places the death of the individuals at the beginning of the II millennium cal BC, coinciding with the Early Bronze Age culture in northern Iberia (Arias and Armendariz, 1998). These findings are not rare because northern Iberia preserves an extraordinary Bronze Age funerary record where caves were selected as burial locations already since the arrival of early farmers during the Neolithic (Ontañón and Armendariz, 2005), but above all in this period when there is an unprecedented increase of burial caves in this area (González-Rabanal, 2022). Both dates overlap, suggesting that the individuals' deaths could have occurred contemporaneously or at least within a short time frame. Therefore, both sites could constitute two synchronous funerary events, although the fact that they were not deposited together does not support this hypothesis. The anthropologic analysis of the skeletons revealed that the human remains belong to two adult male individuals who engaged in high levels of physical activity. The presence of a high degree of robustness, osteophytes and vascular grooves in the TE individual can be interpreted as mobility indicators, supporting that this individual performed high levels of physical activity and, most likely, on rough terrain such as those surrounding the site. In the same way, the identification of some enthesopathies in the axial skeleton and a great robustness degree of the forelimbs of the GS individual suggests intense physical activity on the back. It is probably related to repetitive flexing of the arms. In addition, both individuals presented some pathological conditions, such as dental diseases and osteoarthritis in the case of the TE individual, and Schmörl nodes, scoliosis and an antemortem fracture in the GS individual. The presence of several teeth of the TE individual affected by hypoplasias indicates that this individual suffered at least two nutritional stress events between 2.5-8.5 and 9.5–11.5 years old. The skeletal profile representation shows a generally good state of preservation of the skeletons, as most of the anatomical elements are well represented. This pattern is habitually observed in primary burials (Bello and Andrews, 2006), suggesting that these are the original places where the funerary practices were carried out. This is also supported by partial joints, anatomical associations and the high presence of short and small bones, which are not typical in secondary depositions. However, a low differential preservation of some skeletal remains demonstrates that significant postdepositional processes occurred in modern times at both sites. The disarticulation of the skeletons is quite common in funerary surface deposits conducted in karstic systems because the physicochemical modifications can disturb the primary position of the skeleton (González-Rabanal et al., 2017).

Macroscopic analysis of the human bones identified different lesions

in both individuals (Fig. 4). The cranium of the TE has fresh fractures caused by two primary blunt traumas in the frontal and left parietal bones. They are two depressed/stellate fractures located above the "Hat Brim Line", crossing some cranial sutures. They originated from the point of impact of trauma 1 and 2, with cortical delamination, oblique angles, and smooth edges (Fig. 5). Also, no evidence of bone regeneration has been identified in both traumas. These morphological features suggest that they were produced during the perimortem interval (Sala et al., 2016). The only dry fracture recorded is located in the parieto-occipital area, presenting right angles, jagged edges and concretion along the entire edge. These characteristics indicate that they were produced in a postmortem period due to natural factors during the diagenesis of the deposit (Galloway and Wedel, 2014). Since all fresh fractures of the cranium present the same pattern, it seems plausible to relate all of them to a synchronous event. The precision of the traumatisms and their spatial location in the left frontal and parietal regions support the hypothesis that it is an episode of intentional blunt head injuries rather than an accidental fall (Kremer et al., 2008). This hypothesis is also supported by the absence of other biostratinomic lesions in the postcranial skeleton, including fresh fractures and cut marks. The location of the injuries suggests that they would have been carried out face-to-face by a right-handed individual or from behind by a left-handed individual. In addition, cranial lesions are relatively common in the Bronze Age (Pasini et al., 2019). The traumas' morphological traits suggest that they were probably produced with a sharp-bladed weapon, like a sword or an axe. Different types of Bronze Age axes and swords have been discovered and categorised at the European (Harbison, 1967) and regional levels (Arias and Armendariz, 1998).

On the other hand, the left hemithorax region of the GS individual shows different lesions (Fig. 6). Based on the presence of incomplete fractures, plastic deformation, longitudinal lines, and differences in appearance between the internal and external edges, the fractures of the lateral arches can be considered perimortem. They are consistent with at least one blunt force trauma to the left hemithorax in a posterolateral direction. Instead, the posterior arches' fractures are inconclusive since they could occur both in a perimortem and postmortem interval (Scheirs et al., 2018). In addition, 18 cut marks were identified in the left clavicle and first rib. Both sets of cut marks do not coincide spatially and, therefore, are not the consequence of the repetitive introduction of a double-edged sword, constituting two different incisal stabbing injuries. The repetition of these injuries could indicate that the victim did not defend himself and, therefore, could remain unconscious or dead while carrying them out. Two additional cut marks were placed in the ninth left rib's external part near the sternal end's lower border. They show a crushing section, especially the biggest one, probably due to two sharp stabs. Both cut marks result from two incisive penetrating actions from a weapon with a small blade diameter since it does not touch the adjacent rib. Their morphology and location point to a possible attack with a lateral direction head to head or from behind. The weapon responsible for these lesions could be a knife or a dagger. Schematic representations of daggers are relatively common among the Bronze Age societies of Europe (Bradley, 1998). According to the affected bones, the location of the lesions and their morphological characteristics, none of them can be considered the result of skinning, dismembering or defleshing activities (Binford, 1981). Given the repetitiveness, precision, and focalisation of these cut marks, it seems plausible to suggest that it is a single episode of violence characterised by a series of injuries to the left hemithorax and at the level of the left cervical base. As other types of perimortem lesions have not been detected in the skeleton, some human practices involving fresh fractures or cut marks, such as cannibalism or intentional ritual disarticulation, can be ruled out (Marginedas et al., 2022). One hypothesis could be that the aggressor attacked the victim from behind with a blunt and/or sharp object, causing polytrauma to the left thorax that caused partial or complete loss of consciousness. At that moment, the assailant carried out, also from behind, two incisive penetrating actions in the lower part of the thorax to later cause the death of the individual with the repetitive introduction of a knife at the level of the left cervical area. The cut marks observed in the clavicle and first rib are located where the subclavian and left carotid arteries cross. They are as deadly as the jugular veins or the aorta artery. Therefore, it cannot be ruled out that these cut marks are the result of an action intended to bleed the victim and cause a faster death. This hypothesis would imply that the individual was left-handed. However, it can also be argued that the attacker attacked frontally with a posterolateral angle and was right-handed. An alternative explanation for the cut marks observed in the clavicle and first rib responds to unknown surgical or ritual purposes. In this sense, we have not found other parallels for this type of cut marks in the European prehistoric literature about violence. However, prehispanic ritual violence in the Inca and Maya civilizations show a long set of perimortem modifications resulting from different ritual activities such as cutting the throat, dismembering, opening the chest cavity and decapitation (Tiesler and Cucina, 2006; Marla Toyne, 2011). However, the skeleton of the GS individual does not show cut marks in the cervical vertebrae, sternum, manubrium or the sternal and vertebral ends of the ribs, which can rule out all these actions except the cutting of the throat. Precisely, the cut marks of these prehispanic cases predominate across the bones at the base of the neck (first ribs, clavicles, and cervical vertebra) and the left clavicle is the element most likely to be cut multiple times. This reinforces our hypothesis about the bleeding of the victim either to cause his death or for ritual purposes.

The taphonomic results also demonstrated that significant post-depositional processes were occurring within both burial sites. The distribution of the diagenetic modifications has made it possible to verify that the TE burial site has suffered a more significant post-depositional alteration than the GS burial site. This could be because the TE individual was deposited over the surface of the ledge. In contrast, the GS individual was semi-buried, suggesting that the physicochemical taphonomic processes that occur in karstic contexts have had a more significant influence in the case of the TE individual. The analysis of the long bones breakage patterns has demonstrated that they are dry fractures that occurred during the postmortem interval, indicating their natural origin (Villa and Mahieu, 1991). The fracture parameters are typical of surface deposits and karstic systems, probably related to diagenetic modifications, constituting the most probable causes of the assemblage fragmentation (González-Rabanal et al., 2017). The low presence of thermoalterations or trampling in the human bone assemblages indicates that humans or animals slightly modified both funerary deposits after the deposition of both individuals.

In summary, the morphological features of these modifications confirm that both individuals suffered biostratinomic lesions performed during the perimortem interval, which suggests a likely cause of death. The density of the injuries, the similarities of the burial practices and the contemporaneity of both individuals are coherent with intentional anthropic action, suggesting that they could result from a violent conflict. The profile of the "attacked" individuals can be emphasised, who are adult males, which fits with the primary evidence of intergroup violence in Recent Prehistoric societies of Europe and Iberia, most of them being men in their prime time (Alonso Bercianos and Díaz Navarro, 2021; Díaz Navarro, 2021; Fibiger et al., 2023). The lack of signs of fighting and defence, such as perimortem trauma to the bones of the extremities (Larsen, 2015), allows us to suggest that these violent encounters might occur suddenly and with extreme violence. However, with the current evidence, other questions remain open. Firstly, where were they killed? Outside or inside the cave? The long distance from the burial sites to the cave entrance expresses the desire to hide the corpses. The isolated deposition of these individuals in high and almost inaccessible places in the depths of Cueva Palomera supports intentionality and a typical pattern, so it seems there was a spatial selection for the burial locations. Deposit bodies on the surface of caves in places of difficult access is a common funerary practice in northern Iberia during Recent Prehistory (Ontañón and Armendariz, 2005; González-Rabanal et al., 2017; Armendáriz, 2022), highlighting the possibility that the murders

occurred outside the cave. Secondly, who killed these men? Members of a rival group or members of their community? The absence of grave goods within the sepulchral space does not suggest a specific ritual behaviour of their funerary practice. This would support that those who deposited the bodies did not know or were not interested in leaving any identify trace. However, it is unlikely that the murderers went into such trouble to hide the corpses, although it cannot be discarded. In addition, the scarcity of funerary offerings, ceramics or even ornaments along with human remains is usual within the burial caves of this period and region (Blas Cortina, 2011), although different archaeological materials such as pottery or lithic industry have been identified in contemporaneous burials located in pit fields from the North Castillian Plateau (Esparza Arroyo et al., 2008; Fabián García and Blanco González, 2012; Díaz-Navarro, 2020). And finally, was there any ritual practice on the corpses? The cut marks on the left clavicle and first rib of GS individual indicate precision and skills, so it could not be solely explained as a result of a violent attack.

5.2. Ojo Guareña in its context: violence in northern Iberia during Recent Prehistory

Placing the Ojo Guareña individuals in a geographical context, it is worth noting that 35% of the Iberian individuals with evidence of violence proceed from the upper-middle Ebro valley, and 58% of the incisive-sharp injuries are located in this region (Alonso Bercianos and Díaz Navarro, 2021) (Fig. 1). The Late Neolithic/Chalcolithic site of San Juan Ante Portem Latinam, a collective burial site in a rockshelter compound by more than 300 individuals showed different healed and unhealed lesions consisting of arrowhead injuries and blunt trauma (Vegas et al., 2012). These injuries appeared in adolescents and adult males. But not all the individuals showed perimortem modifications. Therefore, the central hypothesis supports a mass grave from warfare previously and subsequently used for attritional burial (Fernández--Crespo et al., 2018). In this sense, the presence of arrowhead injuries during the Late Neolithic/Chalcolithic transition is relatively common in neighbouring sites as Longar (Soto and Martija, 1995), Las Yurdinas II (Fernández-Crespo, 2017), La Atalayuela (Andrés and Barandiarán, 2004) and La Peña de Marañón (Fernández-Crespo, 2016), as well as a possible case in the Cantabrian cave of Las Cáscaras (Etxeberria and Vegas, 1992). Sharp cranial injuries have also been documented in an occipital from Aizibita (Beguiristain and Etxeberría, 1994), in a left parietal from El Hundido (Alonso, 2015) and in El Mirador, where traumas are evident in four crania, especially in a complete skull of a male individual that shows a blunt blow from an object in the left region of the frontal bone (Iglesias-Bexiga et al., 2022). Other traumatic lesions that seem to denote a violent origin are the Monteggia fractures that appear in the ulna shaft due to the impact of a blunt weapon when the forearm is used to stop a blow. This is the case of some injuries identified in Pico Ramos (Baraybar and La Rua, 1995), Los Llanos, Alto de la Huesera, Las Yurdinas II, San Juan Ante Portam Latinam, Peña del Castillo II or La Mina (Etxebarría et al., 1996). This data seems to testify to some social complexity and probably a significant demographic pressure during the IV and III millennium cal BC that could lead to episodes of interpersonal violence on a small-medium scale and they may have played a remarkable role in the life of these communities.

However, the traumatic injuries for the Bronze Age of northern Iberia, the period to which the two individuals of Ojo Guareña belong, are much less. Some Monteggia-type fractures exist in Las Pajucas (Etxebarría et al., 1996) and Las Arnillas (García-Ruíz, 1992). More interesting is the case of La Saga, where several individuals dated in a simultaneous chronology show perimortem traumatisms in two adult crania and two jaws, as well as cut marks on four adult jaws and a trepanation possibly performed to heal a previous trauma resulting from a violent conflict (Díaz-Navarro, 2020). Another case of violence is constituted by Los Rompizales, a burial pit dated to the Bronze Age, where four individuals were buried. They had cranial perimortem fractures comprising the possible cause of death. However, these individuals were infants and adolescents, so this violence could indicate a ritual practice based on sacrifices (Velasco-Vázquez and Esparza-Arroyo, 2016). On the other hand, although cannibalism can not be considered unequivocally as violent behaviour (Saladié and Rodríguez-Hidalgo, 2017), different butchering activities have also been identified during the Bronze Age in El Mirador, showing considerable evidence of bone modification carried out by humans for consumption, such as butchery, boiling, and toothmarks, which have been interpreted as gastronomic cannibalism. Moreover, six skull cups were specially manipulated, suggesting a ritual treatment of the heads (Cáceres et al., 2007; Marginedas et al., 2022). Finally, the most recent examples of violence come from the Iron Age sites of Las Rabas hillfort and La Hoya village. In Las Rabas, the cranium of a woman suffered two perimortem injuries on the occipital and frontal possibly produced by a spear that entered from behind to the front (Bolado del Castillo et al., 2019), while in La Hoya, the settlement appeared completely burned and many skeletons scattered across the streets in non-funerary contexts (Llanos, 1983). They had multi-evidence of trauma, such as beheadings, amputations and other sharp-force injuries. These patterns constitute a case of a massacre, probably derived from a conflict between rival local communities (Fernández-Crespo et al., 2020).

The finding of similar evidence in neighbouring funerary sites of northern Iberia suggests regular conflicts since the Late Neolithic/Chalcolithic transition (Díaz Navarro, 2021) and with less influence during the Early Bronze Age (González-Rabanal, 2022). Genetic evidence demonstrates that human migrations starred by people with ancestry derived from the steppes of Central Europe (Anthony, 2007) spread across Europe (Haak et al., 2015) introducing the Steppe ancestry in Iberia during the Chalcolithic/Bronze Age transition. This trend was remarkably more robust in northern Iberia, suggesting that an increasing demographic event occurred during the Bronze Age (Olalde et al., 2019), and could trigger a higher density of burials in this area (Armendáriz, 2022), associated with a higher land occupation and therefore a potential resource competition that could lead to small-scale interpersonal or intergroup violent episodes. This argument is in line with the indirect evidence (fortifications, weapons, rock art, etc.) provided by the archaeological record of the Bronze Age, which points towards a time when there could have been more social conflict than the osteoarchaeological analyses tell us.

6. Conclusions

This research provides evidence of violence in Ojo Guareña karst supported by the identification of several perimortem injuries in two adult male individuals dated to the Early Bronze Age, constituting signs of perimortem trauma and their probable cause of death. This study helps to understand the emergence of violence among the early complex societies of the Bronze Age in northern Iberia, complementing the increasing osteoarchaeological evidence of interpersonal violence that suggest an increase of conflicts in the IV and III millennium cal BC. From a methodological perspective, it has been proved that the combination of taphonomic and forensic investigations helps identify and interpret traumatic lesions from the osteoarchaeological record and know the timing of the injuries. Nevertheless, further work is needed, especially on what is called museum archaeology, to study exhaustively human remains from old and amateur excavations stored at museums, never properly analysed or even undated. Only then we will be able to make a deeper approach to enhance our understanding of interpersonal violence, conflict and potential warfare during Recent Prehistory in northern Iberia.

Declaration of competing interest

The authors declare that they have no known competing financial interests or personal relationships that could have appeared to influence

the work reported in this paper.

Data availability

No data was used for the research described in the article.

Acknowledgements

The archaeological materials analysed in this paper are part of B.G.-R.'s Doctoral dissertation funded by the Spanish Economy, Industry and Competitiveness Ministry HAR2016-75605-R and HAR2017-84997-P research projects. M.V.-C. benefited from a Juan de la Cierva Formación Grant (Ref. and FJC2021-047601-I). The research was carried out with the permission of the DG Cultural Heritage of the Regional Government of Castilla y León, which also funded the Carbon Dating of the Cultural Heritage of the Ojo Guareña Cave system (2017–2020). We thank L. Martín-Francés and A. Benito-Calvo (CENIEH) for the archaeology field survey, to A. San Miguel Uriarte, who designed the plans shown in Fig. 2 (modified from the survey of the GEE of 1986) and Fig. 3, and P. Carazo by the photograph of the Sima Dolencias in Fig. 3. We also thank L. Agudo Pérez for the pictures in Fig. 5.

References

Alonso, C., 2015. La tumba colectiva de El Hundido (Monasterio de Rodilla, Burgos) y su ritual funerario durante el Neolítico Final y el Calcolítico. Trab. Prehist. 72, 84–104.
Alonso Bercianos, V., Díaz Navarro, S., 2021. Evidencias osteoarqueológicas de violencia interpersonal e intergrupal en sociedades peninsulares de la Prehistoria Reciente (IV-III milenio aC). BSAA arqueología LXXXVII, 30–60.
AlQahtani, S.J., Hector, M.P., Liversidge, H.M., 2010. The London atlas of human tooth development and eruption. Am. J. Phys. Anthropol. 142, 481–490.
Alt, K.W., Tejedor Rodríguez, C., Nicklisch, N., Roth, D., Szécsényi Nagy, A., Knipper, C., Lindauer, S., Held, P., Lagrán, Í.G.M. de, Schulz, G., Schuerch, T., Thieringer, F., Brantner, P., Brandt, G., Israel, N., Arcusa Magallón, H., Meyer, C., Mende, B.G., Enzmann, F., Dresely, V., Ramsthaler, F., Guillén, J.I.R., Scheurer, E., López Montalvo, E., Garrido Pena, R., Pichler, S.L., Guerra, M.A.R., 2020. A massacre of early Neolithic farmers in the high Pyrenees at Els Trocs, Spain. Sci. Rep. 10, 2131.
Andrés, M.T., Barandiarán, I., 2004. La tumba calcolítica de La Atalayuela, treinta y cinco años después. Saldvie: Estudios de prehistoria y arqueología 85–124.
Anthony, D.W., 2007. The Horse, the Wheel, and Language: How Bronze-Age Riders from the Eurasian Steppes Shaped the Modern World. Princeton University Press.
Arias, P., Armendariz, A., 1998. Aproximación a la Edad del Bronce en la región cantábrica. A Idade do Bronce en Galicia: novas perspectivas. Cadernos do Seminario de Sargadelos 77, 47–80.
Armendáriz, A., 2022. Bronze age burials and funerary practices in Cantabrian Spain. In: Funerary Practices in the Second Half of the Second Millennium BC in Continental Atlantic Europe: from Belgium to the North of Portugal. Archaeopress, pp. 101–127.
Armendariz, J., Irigarai, S., Etxeberria, F., 1994. New evidence of prehistoric arrow wounds in the Iberian Peninsula. Int. J. Osteoarchaeol. 4, 215–222.
Aufderheide, A.C., Rodriguez-Martin, C., 2011. The Cambridge Encyclopedia of Human Paleopathology. Cambridge University Press.
Balzeau, A., Grimaud-Hervé, D., Indriati, E., 2003. Computer tomography scanning of Homo erectus crania Ngandong 7 from Java: internal structure, paleopathology and post-mortem history. Berkala Llmu 35 (3), 133–140.
Baraybar, J.P., La Rua, C. de, 1995. Estudio antropológico de la población de Pico Ramos (Muskiz, Bizkaia). Consideraciones sobre la demografía, salud y subsistencia. Munibe - Ciencias Nat. 47, 151–175.
Beguiristain, M.A., Etxeberría, F., 1994. Lesión craneal seguida de supervivencia en un individuo del dolmen de Aizibita (Cirauqui, Navarra), vol. 2. Cuadernos de Arqueología de la Universidad de Navarra, pp. 49–69.
Bello, S., Andrews, P., 2006. The intrinsic pattern of preservation of human skeletons and its influence on the interpretation of funerary behaviours. In: Gowland, R., Knusel, C. (Eds.), The Social Archaeology of Funerary Remains. Oxbow Books, Oxford, pp. 1–13.
Berger, T.D., Trinkaus, E., 1995. Patterns of trauma among the Neandertals. J. Archaeol. Sci. 22, 841–852.
Binford, L.R., 1981. Bones: Ancient Men and Modern Myths. Academic Press.
Bolado del Castillo, R., Fernández-Vega, P.Á., Carnicero, S., Pérez-Pujol, E., 2019. Nuevos datos para el conocimiento de la Segunda Edad del Hierro en territorio cántabro: la vaguada del castro de Las Rabas (Cervatos, Cantabria). Munibe Antropologia-Arkeologia.
Bradley, R., 1998. Daggers drawn: depictions of bronze age weapons in Atlantic Europe. In: Chippindale, C., Taçon, P.S.C. (Eds.), The Archaeology of the Rock-Art. Cambridge University Press, pp. 130–145.
Bronk Ramsey, C., 1995. Radiocarbon calibration and analysis of Stratigraphy: the OxCal program. Radiocarbon 37, 425–430.
Buikstra, J.E., Ubelaker, D.H., 1994. Standards for data collection from human skeletal remains. Ark. Archeol. Surv. Res. Ser. 44.
Cáceres, I., Lozano, M., Saladié, P., 2007. Evidence for bronze age cannibalism in el Mirador cave (Sierra de Atapuerca, Burgos, Spain). Am. J. Phys. Anthropol. 133, 899–917.
Campillo, D., Baxarias, J., 2008. Quaranta anys de paleopatologia en el Museu d'Arqueologia de Catalunya. Generalitat de Catalunya, Departament de cultura i Mitjans de Comunicació.
Christensen, J., 2004. Warfare in the European neolithic. Acta Archaeol. 75, 129–156.
Cortina, Blas, de, M.Á., 2011. De la caverna al lugar fortificado: una mirada a la edad del bronce en el territorio Astur-Cántabro. Quaderns de Prehistòria i Arqueologia de Castelló 29, 105–134.
Crevecoeur, I., Dias-Meirinho, M.-H., Zazzo, A., Antoine, D., Bon, F., 2021. New insights on interpersonal violence in the Late Pleistocene based on the Nile valley cemetery of Jebel Sahaba. Sci. Rep. 11, 9991.
Díaz Navarro, S., 2021. Violencia intergrupal vs interpersonal: evidencias de lesiones traumáticas en el occidente europeo del VI al III milenio aC. In: Casamayor Mancisidor, S., Portero Hernández, R., Álvarez Fernández, E. (Eds.), La Violencia En La Historia. Ediciones Univesidad de Salamanca, Salamanca, pp. 21–52.
Díaz-Navarro, S., 2020. A new case of prehistoric trepanation and scalping in the Iberian Peninsula: the tomb of La Saga (Cáseda, Navarre). Int. J. Osteoarchaeol. 31, 88–98.
Ehrenreich, B., 1997. Blood Rites: Origins and Passions of War. Henry Holt and Company, New York.
Esparza Arroyo, Á., Delibes de Castro, G., Velasco Vázquez, J., Cruz Sánchez, P.J., 2008. Historia de un golpe en la cabeza: sobre el enterramiento calcolítico del Hoyo 197 de "El Soto de Tovilla" (Tudela de Duero, Valladolid). BSAA arqueología 9–48.
Estabrook, V.H., 2016. Violence and Warfare in the European Mesolithic and Paleolithic. Violence and Warfare Among Hunter-Gatherers.
Etxebarría, F., Baraybar, J.P., Rúa Vaca, C. de la, Aramburu, J.I.V., 1996. Identificación post-mortem y mecanismos de producción de las fracturas diafisarias de cubito. In: Actas del II Congreso Nacional de Paleopatología: (Valencia, octubre de 1993). Ministerio de Educación y Ciencia, pp. 319–323.
Etxeberria, F., Vegas, J.I., 1988. ¿Agresividad o guerra? durante el Neo-enelolítico en la cuenca media del Valle del Ebro, a propósito de S. Juan ante Portam Latinam (Rioja Alavesa). Munibe. Suplemento 105–112.
Etxeberria, F., Vegas, J.I., 1992. Heridas por flecha durante la Prehistoria en la Península Ibérica. Munibe. Suplemento 129–136.
Etxeberria, F., Bandres, A., Herrasti, L., 2005. Muertes violentas determindads a través de los estudios de paleopatología. Munibe - Antropol.-Arkeol. 345–357.
Fabián García, J.F., Blanco González, A., 2012. Cuatro enterramientos calcolíticos en hoyo del Cerro de la Cabeza (Ávila). Complutum 23, 99–120.
Fernández Manzano, J., 1985. La Edad del Bronce: la consolidación de la metalurgia y sus implicaciones socioeconómicas. In: Delibes de Castro, G., Fernández Manzano, J., Romero Carnicero, F., Martín Valls, R. (Eds.), La Prehistoria Del Valle Del Duero, pp. 54–81.
Fernández-Crespo, T., 2016. An arrowhead injury in a late neolithic/early Chalcolithic human cuneiform from the rockshelter of la Peña de Marañón (Navarre, Spain). Int. J. Osteoarchaeol. 26, 1024–1033.
Fernández-Crespo, T., 2017. New evidence of early Chalcolithic interpersonal violence in the middle Ebro valley (Spain): two arrowhead injuries from the swallet of Las Yurdinas II. Int. J. Osteoarchaeol. 27, 76–85.
Fernández-Crespo, T., Schulting, R.J., Ordoño, J., Duering, A., Etxeberria, F., Herrasti, L., Armendariz, Á., Vegas, J.I., Bronk Ramsey, C., 2018. New radiocarbon dating and demographic insights into San Juan ante Portam Latinam, a possible Late Neolithic war grave in North-Central Iberia. Am. J. Phys. Anthropol. 166, 760–771.
Fernández-Crespo, T., Ordoño, J., Llanos, A., Schulting, R.J., 2020. Make a desert and call it peace: massacre at the Iberian Iron Age village of La Hoya. Antiquity 94, 1245–1262.
Fernández-Jalvo, Y., Andrews, P., 2016. Atlas of Taphonomic Identifications: 1001+ Images of Fossil and Recent Mammal Bone Modification. Springer, London.
Fibiger, L., Ahlström, T., Meyer, C., Smith, M., 2023. Conflict, violence, and warfare among early farmers in Northwestern Europe. Proc. Natl. Acad. Sci. U.S.A. 120, e2209481119.
Galloway, A., Wedel, V.L., 2014. Bones of the Skull, the Dentition, and Osseous Structures of the Throat. Broken bones.
García-Ruíz, M., 1992. Análisis de los restos óseos recuperados en el dolmen de corredor de Las Arnillas. Informe mecanografiado inédito.
Gardner, J.C., Smith, F.H., 2006. The paleopathology of the Krapina Neandertals. Period. Biol. 108, 471.
Gómez-Barrera, J.A., Ortega, A.I., Martín, M.Á., García-Diez, M., Fernández, J.J., Val, J. del, 2003. Las manifestaciones gráficas de la Sala de la Fuente (Ojo Guareña, Burgos): dataciones absolutas para la contextualización del arte rupestre, LXVI. Boletín del Seminario de Estudios de Arte y Arqueología, pp. 65–79.
González-Rabanal, B., 2022. Dinámicas de población, dieta y prácticas funerarias de los últimos cazadores-recolectores y primeras sociedades campesinas de la Región Cantábrica. Tesis Doctoral Inédita, Universidad de Cantabria.
González-Rabanal, B., González-Morales, M.R., Marín-Arroyo, A.B., 2017. La tafonomía como marco metodológico para interpretar depósitos funerarios superficiales: estudio de la cueva sepulcral de El Espinoso (Ribadedeva, Asturias). Trab. Prehist. 74, 278–295.
Grupo Espeleológico Edelweiss, 1986. Monografía sobre Ojo Guareña. Kaite, 4-5, p. 415.
Guilaine, J., Zammit, J., 2004. The Origins of War: Violence in Prehistory. John Wiley & Sons.
Haak, W., Lazaridis, I., Patterson, N., Rohland, N., Mallick, S., Llamas, B., Brandt, G., Nordenfelt, S., Harney, E., Stewardson, K., Fu, Q., Mittnik, A., Bánffy, E., Economou, C., Francken, M., Friederich, S., Pena, R.G., Hallgren, F., Khartanovich, V., Khokhlov, A., Kunst, M., Kuznetsov, P., Meller, H., Mochalov, O., Moiseyev, V., Nicklisch, N., Pichler, S.L., Risch, R., Rojo Guerra, M.A., Roth, C.,

Szécsényi-Nagy, A., Wahl, J., Meyer, M., Krause, J., Brown, D., Anthony, D., Cooper, A., Alt, K.W., Reich, D., 2015. Massive migration from the steppe was a source for Indo-European languages in Europe. Nature 522, 207–211.
Harbison, P., 1967. Mediterranean and Atlantic elements in the early bronze age of northern Portugal and Galicia. Madrider Mitteilungen 8, 100–122.
Henry-Gambier, D., Courty, M.A., Crubézy, E., Kervazo, B., Tisnérat-Laborde, N., Valladas, H., 2001. La Sépulture des enfants de Grimaldi (Baoussé-Roussé, Italie) - Anthropologie et palethnologie funéraire des populations de la fin du Paléolithique supérieur. Documents préhistoriques.
Iglesias-Bexiga, J., Yustos, M., Etxeberria-Gabilondo, F., 2022. Life and death in el Mirador cave. Anthropological and palaeopathological analysis of a collective burial. In: Allué, E., Martín, P., Vergès, J.M. (Eds.), Prehistoric Herders and Farmers: A Transdisciplinary Overview to the Archeological Record from El Mirador Cave. Springer International Publishing, Cham, pp. 147–166.
Jantzen, D., Brinker, U., Orschiedt, J., Heinemeier, J., Piek, J., Hauenstein, K., Krüger, J., Lidke, G., Lübke, H., Lampe, R., Lorenz, S., Schult, M., Terberger, T., 2011. A bronze age battlefield? Weapons and trauma in the Tollense valley, north-eastern Germany. Antiquity 85, 417–433.
Jiménez-Brobeil, S.A., Souich, P. du, Al Oumaoui, I., 2009. Possible relationship of cranial traumatic injuries with violence in the south-east Iberian Peninsula from the Neolithic to the Bronze Age. Am. J. Phys. Anthropol. 140, 465–475.
Jiménez-Brobeil, S.A., Roca, M.G., Laffranchi, Z., NáJera, T., Molina, F., 2014. Violence in the central Iberian peninsula during the bronze age: a possible prehistoric homicide. Int. J. Osteoarchaeol. 24, 649–659.
Jordana, F., Parros, J.C., Benezech, M., 2013. Breakage patterns in human cranial bones. Rom. J. Leg. Med. 21, 287–292.
Katzenberg, M.A., Saunders, S.R., 2008. Biological Anthropology of the Human Skeleton. Wiley–Liss, Hoboken NJ.
Keeley, L.H., 1996. War before Civilization. Oxford University Press, USA.
Kimmerle, E.H., Baraybar, J.P., 2008. Skeletal Trauma: Identification of Injuries Resulting from Human Rights Abuse and Armed Conflict. CRC Press.
Kissel, M., Kim, N.C., 2019. The emergence of human warfare: current perspectives. Am. J. Phys. Anthropol. 168 (Suppl. 67), 141–163.
Knüsel, C.J., Robb, J., 2016. Funerary taphonomy: an overview of goals and methods. J. Archaeol. Sci.: Report 10, 655–673.
Kranioti, E.F., Grigorescu, D., Harvati, K., 2019. State of the art forensic techniques reveal evidence of interpersonal violence ca. 30,000 years ago. PLoS One 14, e0216718.
Kremer, C., Racette, S., Dionne, C.-A., Sauvageau, A., 2008. Discrimination of falls and blows in blunt head trauma: systematic study of the hat brim line rule in relation to skull fractures. J. Forensic Sci. 53, 716–719.
Larsen, C.S., 2015. Bioarchaeology: Interpreting Behavior from the Human Skeleton. Cambridge University Press.
Llanos, A., 1983. La Hoya: un poblado del primer milenio antes de Cristo. Diputación Foral de Álava, Vitoria-Gasteiz.
López-Montalvo, E., 2015. Violence in Neolithic Iberia: new readings of Levantine rock art. Antiquity 89, 309–327.
Lovejoy, C.O., Owen Lovejoy, C., Meindl, R.S., Pryzbeck, T.R., Mensforth, R.P., 1985. Chronological metamorphosis of the auricular surface of the ilium: a new method for the determination of adult skeletal age at death. Am. J. Phys. Anthropol. 68, 15–28.
Lovell, N.C., 1997. Trauma analysis in paleopathology. Am. J. Phys. Anthropol. 104, 139–170.
Lyman, R., 1994a. Quantitative Units and Terminology in Zooarchaeology. Am. Antiq. 59, 36–71.
Lyman, R., 1994b. Vertebrate Taphonomy. Cambridge University Press, Cambridge.
Mann, R.W., Hunt, D.R., 2005. Photographic Regional Atlas of Bone Disease: a Guide to Pathologic and Normal Variation in the Human Skeleton. Charles C Thomas Publisher, Springfield.
Marginedas, F., Saladié, P., Rodríguez-Hidalgo, A., Moreno-Ibáñez, M.Á., 2022. Cannibalism at el Mirador cave: Characterization of the processing of human bodies. In: Allué, E., Martín, P., Vergès, J.M. (Eds.), Prehistoric Herders and Farmers: A Transdisciplinary Overview to the Archeological Record from El Mirador Cave. Springer International Publishing, Cham, pp. 187–208.
Marla Toyne, J., 2011. Interpretations of pre-Hispanic ritual violence at Tucume, Peru, from cut mark analysis. Lat. Am. Antiq. 22, 505–523.
Martin, D.L., Harrod, R.P., 2015. Bioarchaeological contributions to the study of violence. Am. J. Phys. Anthropol. 156 (Suppl. 59), 116–145.
Mays, S., 2016. Estimation of stature in archaeological human skeletal remains from Britain. Am. J. Phys. Anthropol. 161, 646–655.
Meindl, R.S., Lovejoy, C.O., 1985. Ectocranial suture closure: a revised method for the determination of skeletal age at death based on the lateral-anterior sutures. Am. J. Phys. Anthropol. 68, 57–66.
Meyer, C., Brandt, G., Haak, W., Ganslmeier, R.A., Meller, H., Alt, K.W., 2009. The Eulau eulogy: bioarchaeological interpretation of lethal violence in Corded Ware multiple burials from Saxony-Anhalt, Germany. J. Anthropol. Archaeol. 28, 412–423.
Meyer, C., Lohr, C., Kürbis, O., Dresely, V., Haak, W., Adler, C., Gronenborn, D., Alt, K. W., 2014. Mass graves of the LBK. In: Proceedings of the British Academy. researchgate.net, pp. 307–325.
Meyer, C., Lohr, C., Gronenborn, D., Alt, K.W., 2015. The massacre mass grave of Schöneck-Kilianstädten reveals new insights into collective violence in Early Neolithic Central Europe. Proc. Natl. Acad. Sci. U.S.A. 112, 11217–11222.
Meyer, C., Kürbis, O., Dresely, V., Alt, K.W., 2018. Patterns of collective violence in the early neolithic of central Europe. In: Dolfini, A., Crellin, R.J., Horn, C., Uckelmann, M. (Eds.), Prehistoric Warfare and Violence: Quantitative and Qualitative Approaches. Springer International Publishing, Cham, pp. 21–38.
Mirazón Lahr, M., Rivera, F., Power, R.K., Mounier, A., Copsey, B., Crivellaro, F., Edung, J.E., Maillo Fernandez, J.M., Kiarie, C., Lawrence, J., Leakey, A., Mbua, E., Miller, H., Muigai, A., Mukhongo, D.M., Van Baelen, A., Wood, R., Schwenninger, J.-L., Grün, R., Achyuthan, H., Wilshaw, A., Foley, R.A., 2016. Inter-group violence among early Holocene hunter-gatherers of West Turkana, Kenya. Nature 529, 394–398.
Molloy, B., Horn, C., 2020. Weapons, Warriors and warfare in bronze age Europe. In: Dwyer, P., Damousi, J. (Eds.), The Cambridge World History of Violence. Cambridge University Press, Cambridge, pp. 117–141.
Montgomery, P.Q., Williams, H.O.L., Reading, N., Stringer, C.B., 1994. An assessment of the temporal bone lesions of the broken Hill cranium. J. Archaeol. Sci. 21, 331–337.
Moreno-Ibáñez, M.Á., Saladié, P., Morales, J.I., Cebrià, A., Fullola, J.M., 2021. Was it an axe or an adze? A cranial trauma case study from the Late Neolithic - Chalcolithic site of Cova Foradada (Calafell, Spain). Int. J. Paleopathol. 32, 23–30.
Nájera, T., Molina González, F., Jiménez-Brobeil, S.A., Al Oumaoui, I., Roca, M.G., Navarro, M.H., Fernández Martín, S., 2010. Un ejemplo de violencia interpersonal extrema durante la Edad del Bronce: el enterramiento 60 de la Motilla del Azuer, vol. 20. Cuadernos de Prehistoria y Arqueología de la Universidad de Granada, pp. 381–394.
Navazo, M., Benito-Calvo, A., Alonso-Alcalde, R., Alonso, P., Fuente, H. de la, Santamaría, M., Santamaría, C., Álvarez-Vena, A., Arnold, L.J., Iriarte-Chiapusso, M. J., Demuro, M., Lozano, M., Ortiz, J.E., Torres, T., 2021. Late Neanderthal subsistence strategies and cultural traditions in the northern Iberia Peninsula: insights from Prado Vargas, Burgos, Spain. Quat. Sci. Rev. 254, 106795.
Olalde, I., Mallick, S., Patterson, N., Rohland, N., Villalba-Mouco, V., Silva, M., Dulias, K., Edwards, C.J., Gandini, F., Pala, M., Soares, P., Ferrando-Bernal, M., Adamski, N., Broomandkhoshbacht, N., Cheronet, O., Culleton, B.J., Fernandes, D., Lawson, A.M., Mah, M., Oppenheimer, J., Stewardson, K., Zhang, Z., Jiménez Arenas, J.M., Toro Moyano, I.J., Salazar-García, D.C., Castanyer, P., Santos, M., Tremoleda, J., Lozano, M., García Borja, P., Fernández-Eraso, J., Mujika-Alustiza, J. A., Barroso, C., Bermúdez, F.J., Viguera Mínguez, E., Burch, J., Coromina, N., Vivó, D., Cebrià, A., Fullola, J.M., García-Puchol, O., Morales, J.I., Oms, F.X., Majó, T., Vergès, J.M., Díaz-Carvajal, A., Ollich-Castanyer, I., López-Cachero, F.J., Silva, A.M., Alonso-Fernández, C., Delibes de Castro, G., Jiménez Echevarría, J., Moreno-Márquez, A., Pascual Berlanga, G., Ramos-García, P., Ramos-Muñoz, J., Vijande Vila, E., Aguilella Arzo, G., Esparza Arroyo, Á., Lillios, K.T., Mack, J., Velasco-Vázquez, J., Waterman, A., Benítez de Lugo Enrich, L., Benito Sánchez, M., Agustí, B., Codina, F., Prado, G. de, Estalrrich, A., Fernández Flores, Á., Finlayson, C., Finlayson, G., Finlayson, S., Giles-Guzmán, F., Rosas, A., Barciela González, V., García Atiénzar, G., Hernández Pérez, M.S., Llanos, A., Carrión Marco, Y., Collado Beneyto, I., López-Serrano, D., Sanz Tormo, M., Valera, A.C., Blasco, C., Liesau, C., Ríos, P., Daura, J., Pedro Michó, M.J. de, Diez-Castillo, A.A., Flores Fernández, R., Francès Farré, J., Garrido-Pena, R., Gonçalves, V.S., Guerra-Doce, E., Herrero-Corral, A.M., Juan-Cabanilles, J., López-Reyes, D., McClure, S.B., Merino Pérez, M., Oliver Foix, A., Sanz Borràs, M., Sousa, A.C., Vidal Encinas, J.M., Kennett, D.J., Richards, M.B., Werner Alt, K., Haak, W., Pinhasi, R., Lalueza-Fox, C., Reich, D., 2019. The genomic history of the Iberian Peninsula over the past 8000 years. Science 363, 1230–1234.
Ontañón, R., Armendariz, A., 2005. Cuevas y megalitos: los contextos sepulcrales colectivos en la Prehistoria reciente cantábrica. Munibe - Antropol.-Arkeol. 57, 275–286.
Ortega, A.I., Martín, M.Á., 1986. La Arqueología del Karst de Ojo Guareña. In: Grupo Espeleológico Edelweiss. Monografía Sobre Ojo Guareña. Kaite, Estudios de Espeleología Burgalesa, pp. 331–389.
Ortega, A.I., Martín, M.Á., 2001. La arqueología del complejo kárstico de Ojo Guareña (Merindad de Sotoscueva, Burgos). Boletín de la Sociedad Española de Espeleología y Ciencias del Karst. SEDECK 29–35.
Ortega, A.I., Martín, M.Á., 2015. El arte rupestre de Ojo Guareña: singularidad y pervivencia en el tiempo. Cubía 19, 10–23.
Ortega, A.I., Martín, M.Á., 2023. Investigaciones de Adolfo Eraso en Ojo Guareña y Atapuerca y síntesis del conocimiento actual del karst en ambas zonas. In: SEDECK (Ed.), Homenaje a Adolfo Eraso Romero, Perfil Humano Y Científico. Sociedad Española de Espeleología y Ciencias del Karst (SEDECK), pp. 35–88.
Ortega, A.I., Martín, M.Á., Grupo Espeleológico Edelweiss, 2013. Cuevas de Ojo Guareña. Una visión de la mano del Grupo Espeleológico Edelweiss. Diputación Provincial de Burgos.
Ortega, A.I., Martín, M.Á., García-Diez, M., 2020. Palaeolithic creation and later visits of symbolic spaces: radiocarbon AMS dating and cave art in the Sala de las Pinturas in Ojo Guareña (Burgos, Spain). Archaeol. Anthropol. Sci. 12, 240.
Ortega, A.I., Ruiz, F., Martín, M.Á., Benito-Calvo, A., Vidal, M., Bermejo, L., Karampaglidis, T., 2021a. Prehistoric Human Tracks in Ojo Guareña Cave System (Burgos, Spain): the Sala and Galerías de las Huellas. In: Pastoors, A., Lenssen-Erz, T. (Eds.), Reading Prehistoric Human Tracks: Methods & Material. Springer International Publishing, Cham, pp. 317–342.
Ortega, A.I., Martín, M.Á., Ruiz, F., Benito-Calvo, A., Vidal-Cordasco, M., García-Díez, M., 2021b. Nuevas investigaciones y dataciones arqueológicas en Ojo Guareña (Merindad de Sotoscueva, Burgos), pp. 51–84. Boletín de la Sociedad Española de Espeleología y Ciencias del Karst 16.
Otterbein, K.F., 1997. The origins of war. Crit. Rev. 11, 251–277.
Pasini, A., Gualdi-Russo, E., Scianò, F., Thun Hohenstein, U., 2019. Violence in the Early Bronze Age. Diagnosis of skull lesions using anthropological, taphonomic and scanning electron microscopy techniques. Forensic Sci. Med. Pathol. 15, 324–328.
Pokines, J.T., Symes, S.A., 2014. Manual of Forensic Taphonomy. CRC Press, London.
Reimer, P.J., Austin, W.E.N., Bard, E., Bayliss, A., Blackwell, P.G., Ramsey, C.B., Butzin, M., Cheng, H., Lawrence Edwards, R., Friedrich, M., Grootes, P.M., Guilderson, T.P., Hajdas, I., Heaton, T.J., Hogg, A.G., Hughen, K.A., Kromer, B.,

Manning, S.W., Muscheler, R., Palmer, J.G., Pearson, C., Plicht van der, J., Reimer, R.W., Richards, D.A., Marian Scott, E., Southon, J.R., Turney, C.S.M., Wacker, L., Adolphi, F., Büntgen, U., Capano, M., Fahrni, S.M., Fogtmann-Schulz, A., Friedrich, R., Köhler, P., Kudsk, S., Miyake, F., Olsen, J., Reinig, F., Sakamoto, M., Sookdeo, A., Talamo, S., 2020. The IntCal20 northern Hemisphere radiocarbon age calibration curve (0–55 cal kBP). Radiocarbon 62, 725–757.
Richardson, P.R.K., 1980. Carnivore damage to antelope bones and its archaeological implications. Paleontologies Africana 23, 109–125.
Roksandic, M., 2006. Violence in the mesolithic. Documenta Praehistorica 33, 165–182.
Roksandic, M., Djurić, M., Rakocević, Z., Seguin, K., 2006. Interpersonal violence at Lepenski Vir mesolithic/neolithic complex of the Iron Gates Gorge (Serbia-Romania). Am. J. Phys. Anthropol. 129, 339–348.
Sala, N., Arsuaga, J.L., Pantoja-Pérez, A., Pablos, A., Martínez, I., Quam, R.M., Gómez-Olivencia, A., Bermúdez de Castro, J.M., Carbonell, E., 2015. Lethal interpersonal violence in the middle Pleistocene. PLoS One 10, e0126589.
Sala, N., Pantoja-Pérez, A., Arsuaga, J.L., Pablos, A., Martínez, I., 2016. The Sima de los Huesos Crania: analysis of the cranial breakage patterns. J. Archaeol. Sci. 72, 25–43.
Saladié, P., Rodríguez-Hidalgo, A., 2017. Archaeological evidence for cannibalism in prehistoric Western Europe: from Homo antecessor to the bronze age. J. Archaeol. Method Theor 24, 1034–1071.
Sánchez-Barba Muñoz, L.P., Vijande Vila, E., Rubio Salvador, Á., Alemán Aguilera, I., Díaz-Zorita Bonilla, M., Moreno Márquez, A., Domínguez-Bella, S., Ramos Muñoz, J., Botella López, M.C., 2019. Possible interpersonal violence in the neolithic necropolis of Campo de Hockey (San Fernando, Cádiz, Spain). Int. J. Paleopathol. 27, 38–45.
Sauer, N.J., 1998. The timing of injuries and manner of death: distinguishing among antemortem, perimortem and postmortem trauma. In: Reichs, K.J. (Ed.), Forensic Osteology: Advances in the Identification of Human Remains. Charles C. Thomas, Springfield, IL, pp. 321–331.
Scheirs, S., Langenhorst, W., Malgosa, A., Ortega-Sánchez, M., McGlynn, H., Santos, C., Jordana, X., Rodriguez-Baeza, A., Galtés, I., 2018. Perimortem fracture pattern in ribs by blunt force trauma. Int. J. Leg. Med. 132, 1205–1213.
Scheuer, L., Black, S., 2000. Developmental Juvenile Osteology. Academic Press, London.
Schotsmans, E.M.J., Márquez-Grant, N., Forbes, S.L., 2017. Taphonomy of Human Remains: Forensic Analysis of the Dead and the Depositional Environment. Wiley, London.
Schulting, R., 2009. 15. Skeletal evidence and contexts of violence in the European mesolithic and neolithic. Soc. Archaeol. Funerary Remains 1, 224.
Schulting, R.J., Fibiger, L., 2012. Sticks, Stones, and Broken Bones: Neolithic Violence in a European Perspective. OUP, Oxford.
Silva, A.M., Marques, R., 2010. An arrowhead injury in a Neolithic human axis from the natural cave of Lapa do Bugio (Sesimbra, Portugal). Anthropological science. J. Anthropol. Soc. Nippon = Jinruigaku zasshi 118, 185–189.
Silva, A.M., Boaventura, R., Ferreira, M.T., Marques, R., 2012. Skeletal Evidence of Interpersonal Violence from Portuguese Late Neolithic Collective Burials: an Overview. Sticks, Stones, and Broken Bones: Neolithic Violence in a European Perspective. Oxford University Press, Oxford, pp. 317–340.
Smith, B.H., 1984. Patterns of molar wear in hunger-gatherers and agriculturalists. Am. J. Phys. Anthropol. 63, 39–56.
Sorg, M.H., Haglund, W.D., 1996. Forensic Taphonomy: the Postmortem Fate of Human Remains. CRC Press, London.
Soriano, I., Gibaja, J.F., Vila, L., 2015. Open warfare or the odd skirmish? Bell beaker violence in the north-eastern Iberian peninsula. Oxf. J. Archaeol. 34, 157–183.
Soto, S.I., Martija, J.A., 1995. Violencia y muerte en la prehistoria: el hipogeo de Longar (Viana, Navarra). Rev. Arqueol. 16, 16–29.
Stodder, A.L.W., 2018. Taphonomy and the nature of archaeological assemblages. In: Biological Anthropology of the Human Skeleton. John Wiley & Sons, Inc., Hoboken, NJ, USA, pp. 73–115.
Szilvássy, J., 1977. Estimation of age by the sternal articular surfaces of the clavicle. Beitrage zur gerichtlichen Medizin 35, 343–345.
Teschler-Nicola, M., 2012. The early Neolithic site Asparn/Schletz (Lower Austria): anthropological evidence of interpersonal violence. In: Schulting, R., Fibiger, L. (Eds.), Sticks, Stones, and Broken Bones: Neolithic Violence in a European Perspective. Oxford University Press, pp. 101–120.
Thorpe, I.J.N., 2005. The ancient origins of warfare and violence. In: Warfare, Violence and Slavery in Prehistory. British Archaeological Report. International Series, 1374, pp. 1–18.
Tiesler, V., Cucina, A., 2006. Procedures in human Heart extraction and ritual meaning: a taphonomic assessment of Anthropogenic marks in classic Maya skeletons. Lat. Am. Antiq. 17, 493–510.
Trinkaus, E., Buzhilova, A.P., 2012. The death and burial of sunghir 1. Int. J. Osteoarchaeol. 22, 655–666.
Trinkaus, E., Svoboda, J., 2006. Early Modern Human Evolution in Central Europe: the People of Dolní Věstonice and Pavlov. Oxford University Press.
Trinkaus, E., Zimmerman, M.R., 1982. Trauma among the Shanidar Neandertals. Am. J. Phys. Anthropol. 57, 61–76.
Trotter, M., Gleser, G.C., 1952. Estimation of stature from long bones of American Whites and Negroes. Am. J. Phys. Anthropol. 10, 463–514.
Uribarri, J.L., Liz, C., 1973. El arte rupestre de" Ojo Guareña". La cueva de Kaite. Trab. Prehist. 30, 69–120.
Vegas, J.I., Armendariz, A., Etxeberria, F., Fernández, M.S., Herrasti, L., 2012. Prehistoric violence in northern Spain: San Juan ante Portam Latinam. In: Schulting, R.J., Fibiger, L. (Eds.), Sticks, Stones and Broken Bones. Neolithic Violence in a European Perspective. Oxbow, Oxford, pp. 265–302.
Velasco-Vázquez, J., Esparza-Arroyo, Á., 2016. Muertes ritualizadas en la Edad del Bronce de la Península Ibérica: un enterramiento inusual en Los Rompizales (Quintanadueñas, Burgos). Munibe - Antropol.-Arkeol. 67, 75–103.
Villa, P., Mahieu, E., 1991. Breakage patterns of human long bones. J. Hum. Evol. 21, 27–48.
Wahl, J., Trautmann, I., 2012. The Neolithic Massacre at Talheim: A pivotal Find in Conflict Archaeology. Sticks, Stones, and Broken Bones: Neolithic Violence in a European Perspective, pp. 77–100.
Walker, P.L., 2001. A bioarchaeological perspective on the history of violence. Annu. Rev. Anthropol. 30, 573–596.
White, T.D., Folkens, P.A., 2005. The Human Bone Manual. Elsevier, San Diego.
Wu, X.-J., Schepartz, L.A., Liu, W., Trinkaus, E., 2011. Antemortem trauma and survival in the late Middle Pleistocene human cranium from Maba, South China. Proc. Natl. Acad. Sci. U.S.A. 108, 19558–19562.
Zollikofer, C.P.E., León, M.S.P. de, Vandermeersch, B., Lévêque, F., 2002. Evidence for interpersonal violence in the St. Césaire Neanderthal. Proc. Natl. Acad. Sci. USA 99, 6444–6448.